

Accidental ingestion of 35% hydrogen peroxide

Sean Pritchett MD¹, Daniel Green MD², Peter Rossos MD²

S Pritchett, D Green, P Rossos. Accidental ingestion of 35% hydrogen peroxide. *Can J Gastroenterol* 2007;21(10):665-667.

Hydrogen peroxide is a commonly used oxidizing agent with a variety of uses depending on its concentration. Ingestion of hydrogen peroxide is not an uncommon source of poisoning, and results in morbidity through three main mechanisms: direct caustic injury, oxygen gas formation and lipid peroxidation. A case of a 39-year-old man who inadvertently ingested 250 mL of unlabelled 35% hydrogen peroxide intended for natural health use is presented. Hydrogen peroxide has purported benefits ranging from HIV treatment to cancer treatment. Its use in the natural health industry represents an emerging source for accidental poisonings.

Key Words: *Caustic injury; Hydrogen peroxide; Portal vein gas*

Hydrogen peroxide is a commonly used oxidizing agent with a variety of uses depending on its concentration. Although historically it has been used for medicinal purposes such as wound irrigation, its toxic effects preclude its routine use. Ingestion of hydrogen peroxide is not an uncommon cause of poisoning, and results in morbidity through three main mechanisms: direct caustic injury, oxygen gas formation and lipid peroxidation. The growing naturopathic health industry has promoted the use of hydrogen peroxide in treating a wide variety of medical conditions. A case of a 39-year-old man who inadvertently ingested 250 mL of unlabelled 35% hydrogen peroxide intended for natural health use is presented.

CASE PRESENTATION

A healthy 39-year-old man presented to the emergency department following the accidental ingestion of one-half of a 500 mL container of 35% hydrogen peroxide. The hydrogen peroxide was in an unlabelled container in a friend's refrigerator and was mistaken for water. Immediately after ingesting the hydrogen peroxide, he realized it was a caustic substance and drank 500 mL of water to induce vomiting. A small amount of hematemesis was noted. He experienced mild epigastric pain without shortness of breath or oropharyngitis.

On arrival to the emergency department, he was hemodynamically stable and in no respiratory distress. The oral cavity and oropharynx were slightly erythematous and the abdominal examination revealed mild epigastric tenderness but no distension, and normal bowel sounds.

Intravenous (IV) fluids and IV pantoprazole, 40 mg twice per day, were initiated. Bloodwork was normal except for

L'ingestion accidentelle de peroxyde d'hydrogène 35 %

Le peroxyde d'hydrogène est un oxydant courant aux usages variés, selon sa concentration. L'empoisonnement par ingestion de peroxyde d'hydrogène n'est pas rare et provoque une morbidité par trois principaux mécanismes : lésion directe par substance corrosive, formation de gaz oxygène et peroxydation lipidique. Est présenté le cas d'un homme de 39 ans qui a ingéré par inadvertance 250 mL de peroxyde d'hydrogène 35 % non étiquetés et destiné à une utilisation en santé naturelle. Le peroxyde d'hydrogène procure de prétendus bienfaits dans le traitement de toutes sortes de maladies, du VIH jusqu'au cancer. Son utilisation dans l'industrie des produits de santé naturels représente une source émergente d'empoisonnements accidentels.

mild leukocytosis; the chest x-ray was normal. Esophagogastroduodenoscopy was performed to assess the severity of the caustic injury. This revealed a normal oral cavity and normal esophagus. The stomach revealed grade 2 diffuse caustic mucosal injury of the entire stomach, including the cardia, characterized by superficial erosions with exudates and edema (Figure 1). The duodenum only revealed a few scattered superficial erosions in the first and second parts (Figure 2).

A computed tomography scan of the abdomen revealed portal venous gas (Figure 3), extravisceral gas in the region of the gastrohepatic ligament and possible pneumatosi of the stomach and duodenum.

On subsequent history, the patient indicated that the 35% hydrogen peroxide was used for natural health purposes, including aiding in digestion. It was kept in the refrigerator to help prolong its shelf-life. The patient recovered well, and was discharged from hospital on the third day with no complications.

DISCUSSION

Hydrogen peroxide is a clear, colourless, odourless oxidizing agent found in concentrations ranging from 3% to 90%. Three per cent solutions are used as common household disinfectants, and are therefore a common source of accidental poisonings, especially in children. In one study (1) of more than 95,000 toxic exposures reported to a poison control centre over three years, 0.34% were due to hydrogen peroxide and of these, 60% occurred in children younger than six years of age, and 85% occurred through ingestion. Fatalities in both adults and children have been reported with ingestion of 35%

¹University of Toronto; ²Division of Gastroenterology, University of Toronto, Toronto, Ontario

Correspondence and reprints: Dr Sean Pritchett, University of Toronto, 88 Kingsmount Park Road, Toronto, Ontario M4L 3L4.

Telephone 647-204-9105, fax 416-340-5335, e-mail sean.pritchett@utoronto.ca

Received for publication July 27, 2006. Accepted August 12, 2006

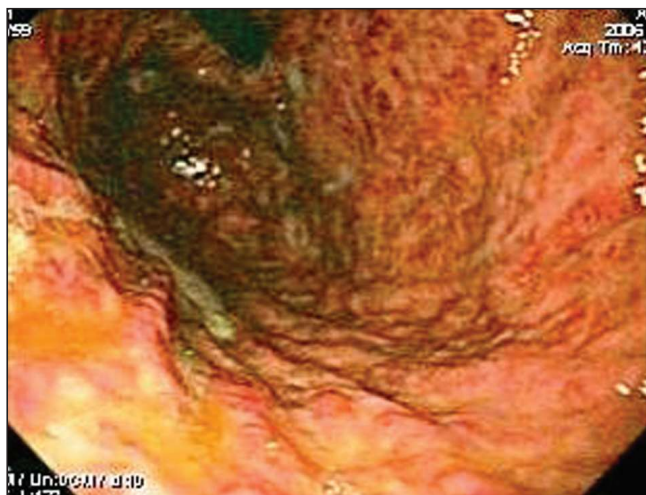

Figure 1) Endoscopy revealing grade 2 diffuse caustic mucosal injury involving the entire stomach including the cardia seen on retroflexion after ingestion of 250 mL of 35% hydrogen peroxide

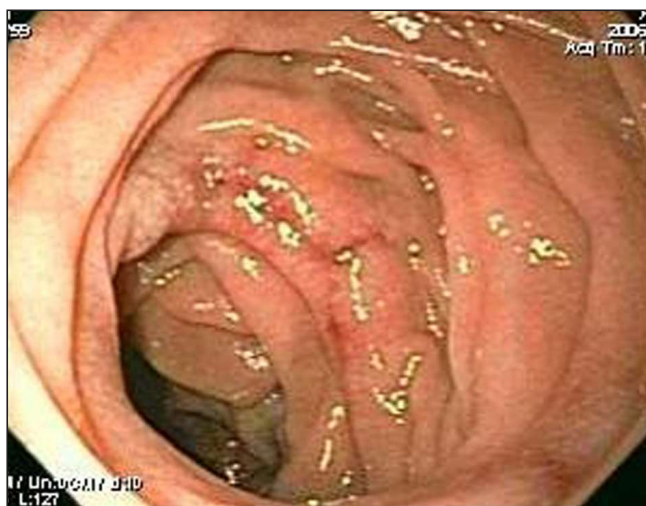

Figure 2) Endoscopy showing mild erosions in the duodenum

hydrogen peroxide (1,2). A concentration of 35% is technical grade or food grade hydrogen peroxide, and can be purchased in many health food stores because it is reputed to have multiple health benefits including being useful in the treatment of HIV, cancer, chronic obstructive pulmonary disease and Alzheimer's dementia (3). Higher concentrations of up to 90% are used as rocket fuel.

Hydrogen peroxide is relatively unstable and will rapidly decompose, through an exothermic reaction, into water and oxygen in the presence of alkali, metals and the enzyme catalase, which is found in mucous membranes, liver, kidney, red blood cells and bone marrow (1). There are three main mechanisms of toxicity from hydrogen peroxide: caustic injury, oxygen gas formation and lipid peroxidation (1).

Ingestion of 3% hydrogen peroxide usually results in only mild gastritis, unless ingested in large quantities (2). Ingestion of more concentrated forms including 35% hydrogen peroxide can produce severe gastrointestinal erosion, ulceration and perforation (1). Hydrogen peroxide enteritis with 3% solution can cause instant bubbling on the mucosal surface followed by a whitening of the mucosa termed the 'snow white' sign (4).

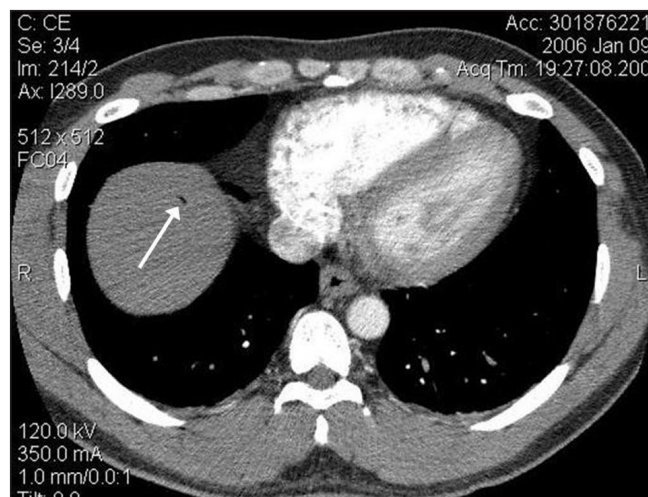


Figure 3) Computed tomography scan of the abdomen showing the presence of portal venous gas (arrow)

This phenomenon is thought to be secondary to absorption of hydrogen peroxide into the epithelial interstices and capillaries, and the subsequent blanching caused by formation of microbubbles of molecular oxygen (4). Caustic injury can also occur in the airway if aspirated or inhaled, and can lead to subglottic stenosis and laryngospasm requiring intubation and mechanical ventilation (1).

The volume of oxygen liberated from the decomposition of hydrogen peroxide can be considerable, with 30 mL of 35% hydrogen peroxide yielding 3.5 L of oxygen (1). This rapid release of oxygen can lead to hollow viscous perforation (1). If the amount of oxygen exceeds the maximum solubility in blood, it may lead to gas embolism particularly in the portal venous system, gastric wall (5) and brain (6). Gas embolism in the brain presents similar to ischemic stroke and has been successfully treated with hyperbaric oxygen therapy (6).

Lipid peroxidation from ingested hydrogen peroxide can lead to direct cytotoxic effects (1).

Despite the potential for severe injury from hydrogen peroxide, it has been used extensively throughout medical history. One per cent to 3% solutions were used for wound irrigation and as rectal enemas, but gas embolism and rectal ulceration limited its use (1). A dilute IV version of hydrogen peroxide was administered for the treatment of AIDS, but resulted in hemolysis and eventually death (1). The use of hydrogen peroxide as a natural remedy is generally based on the premise that it is a concentrated source of potential oxygen. It is administered orally, through IV injection and through inhalation, for conditions such as COPD to help oxygenate the lung and in diabetes mellitus to improve glucose utilization (3). Possible mechanisms of action include vasodilation, strengthening the immune system and stimulating prostaglandin synthesis (3). Thirty-five per cent hydrogen peroxide is available from commercial health food stores, is typically stored in a refrigerator or freezer to retard decomposition, and is diluted to achieve the desired concentration. Despite the little evidence on its benefits and well-documented accidental poisonings, there is continued use and availability of hydrogen peroxide for such health applications.

Management of hydrogen peroxide exposures depends on the severity of ingestion and includes airway management,

frequent monitoring, and diagnosis and therapy of associated complications. Due to the rapid decomposition, gut decontamination is not required. In the present case, the immediate ingestion of 500 mL of water following the hydrogen peroxide may have prevented more serious oropharyngeal and esophageal injury. Both x-ray and computed tomography are useful for ruling out viscous perforation and air embolism. Endoscopy should be performed in all patients (except if perforation is suspected or the patient is hemodynamically unstable) because signs and symptoms do not consistently correlate with the extent of injury, making endoscopy the only reliable method to assess for injury (7). Endoscopic assessment of injury severity within 24 h can be used to risk stratify patients because the severity of mucosal injury strongly correlates with the risk of death and systemic complications (8). Strictures occur most frequently in the esophagus and generally develop between six and 12 weeks (8). Consequently, routine follow-up endoscopy may be indicated in patients with esophageal injury. One trial (2) reported using IV cimetidine when there was evidence of gastric erosions or ulcers, but none have documented using proton pump inhibitors. In the present case, IV pantoprazole, 40 mg twice a day, was used, and the patient had resolution of all abdominal pain symptoms. For cerebral gas embolism, hyperbaric oxygen therapy has been used successfully (6).

Most exposures to hydrogen peroxide are with the 3% solution of hydrogen peroxide, which results in little or no morbidity.

However, the storage and use of 35% hydrogen peroxide for natural health benefits results in an emerging source for more serious ingestions. Thirty-five per cent hydrogen peroxide can be lethal when ingested, and needs to be treated with caution and stored appropriately. Public awareness and regulation of the use of this substance is required.

REFERENCES

1. Watt BE, Proudfoot AT, Vale JA. Hydrogen peroxide poisoning. *Toxicol Rev* 2004;23:51-7.
2. Henry MC, Wheeler J, Mofenson HC, et al. Hydrogen peroxide 3% exposures. *J Toxicol Clin Toxicol* 1996;34:323-7.
3. Yutis PI. Oxygen to the Rescue: Oxygen Therapies and How They Help Overcome Disease, Promote Repair, and Improve Overall Function. New Jersey: Basic Health Publications Inc, 2003.
4. Bilotta JJ, Waye JD. Hydrogen peroxide enteritis: The "snow white" sign. *Gastrointest Endosc* 1989;35:428-30.
5. Ghai S, O'Malley ME. Portal vein gas resulting from ingestion of hydrogen peroxide. *AJR Am J Roentgenol* 2003;181:1719-20.
6. Mullins ME, Beltran JT. Acute cerebral gas embolism from hydrogen peroxide ingestion successfully treated with hyperbaric oxygen. *J Toxicol Clin Toxicol* 1998;36:253-6.
7. Satar S, Topal M, Kozaci N. Ingestion of caustic substances by adults. *Am J Ther* 2004;11:258-61.
8. Poley JW, Steyerberg EW, Kuipers EJ, et al. Ingestion of acid and alkaline agents: Outcome and prognostic value of early upper endoscopy. *Gastrointest Endosc* 2004;60:372-7.