

See discussions, stats, and author profiles for this publication at: <https://www.researchgate.net/publication/309542127>

# Acquired tracheo–esophageal fistula from disc battery in a child: A case report and review of literature

Article · January 2016

DOI: 10.4103/2394-2010.193183

---

CITATIONS

0

---

READS

25

3 authors, including:



**Umar Abubakar**

Usmanu Danfodiyo University Sokoto

28 PUBLICATIONS 21 CITATIONS

SEE PROFILE



**Solomon Ukwuani**

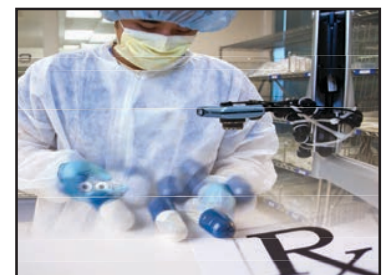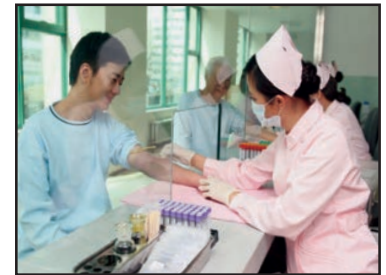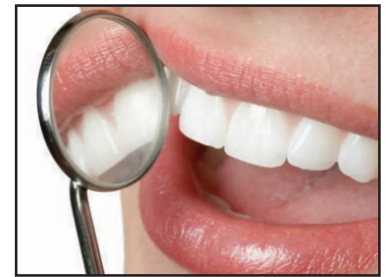Usmanu Danfodiyo University Teaching Hos...

6 PUBLICATIONS 0 CITATIONS

SEE PROFILE

ISSN 2394-2010

Volume 3 | Issue 3 | Sep-Dec 2016



# Journal of Health Research & Reviews

[www.jhrr.org](http://www.jhrr.org)

Official Publication of  
Academy of Advanced Dental Research

Medknow

 Wolters Kluwer

# Acquired tracheo-esophageal fistula from disc battery in a child: A case report and review of literature

Umar Abubakar, Salisu Ismail, Solomon I Ukwuani

Department of Surgery, Cardiothoracic Surgery Unit, Usmanu Danfodiyo University Teaching Hospital, Usmanu Danfodiyo University, Sokoto, Nigeria

Received: 21-03-16

Accepted: 09-08-16

Published: 02-11-16

## ABSTRACT

Disc battery ingestion has increased drastically due to the fact that most household devices use these batteries. Children have access to these devices either as their toys which they play with or as devices that are used on daily basis such as remote control and watches. Children place things in their mouth, using it as a means of exploring their environment. It is common for these batteries to get impacted in the esophagus and if not removed immediately will cause liquifactive necrosis leading to perforation into the trachea which is closely related to the esophagus. We report a case of disc battery ingestion that presented to us with a tracheo-esophageal fistula. We also reviewed literature related to this pathology.

**Keywords:** Disc battery, ingestion, tracheo-esophageal fistula

## INTRODUCTION

Devices with disc battery have become very common worldwide.<sup>[1]</sup> Children place things in their mouth, using it as a means of exploring their environment, and consequently, ingestion of these foreign objects is common in early childhood. This is said to be common in toddlers.<sup>[2]</sup> An esophageal foreign body may lodge in any of the narrowed parts of the esophagus. If a battery gets impacted, it may penetrate the esophageal wall and cause a tracheo-esophageal fistula.<sup>[3]</sup> We report a case of disc battery ingestion in a child who presented to us with a tracheo-esophageal fistula from a disc battery he ingested.

## CASE REPORT

A 20-month-old male child was referred to us with 7-month history of choking during feeding. This was associated with

episodes of cough and vomiting. He also had a history of recurrent respiratory tract infections warranting several hospital admissions. There was a history of significant weight loss since the onset of symptoms. There was a preceding history of ingestion of a button cell-type battery about 7 months ago, which was removed via esophagoscopy after about 30 h, and the procedure was said to have been difficult and traumatic. Symptoms were noticed a day after this procedure.

Esophagogram revealed a tract connecting the trachea and cervical esophagus at the level of the C5/C6. There was no proximal or distal narrowing, and lung fields were clear [Figure 1].

He had a repair of tracheo-esophageal fistula through a lateral neck incision. The fistulous tract was mobilized and transected [Figures 2 and 3]. Tracheal and esophageal ends were closed in two layers, and a muscle flap was placed between them.

The patient recovered well and was discharged on the 6<sup>th</sup> postoperative day. Postrepair esophagogram did not reveal any fistulous connection between the trachea and esophagus.

This is an open access article distributed under the terms of the Creative Commons Attribution-NonCommercial-ShareAlike 3.0 License, which allows others to remix, tweak, and build upon the work non-commercially, as long as the author is credited and the new creations are licensed under the identical terms.

**For reprints contact:** reprints@medknow.com

**How to cite this article:** Abubakar U, Ismail S, Ukwuani SI. Acquired tracheo-esophageal fistula from disc battery in a child: A case report and review of literature. J Health Res Rev 2016;3:119-22.

**Address for correspondence:** Dr. Umar Abubakar,  
Department of Surgery, Cardiothoracic Surgery Unit, Usmanu  
Danfodiyo University Teaching Hospital, Usmanu Danfodiyo  
University, Sokoto, Nigeria.  
E-mail: drzuru@yahoo.com

### Access this article online

#### Quick Response Code:



#### Website:

www.jhrr.org

#### DOI:

10.4103/2394-2010.193183

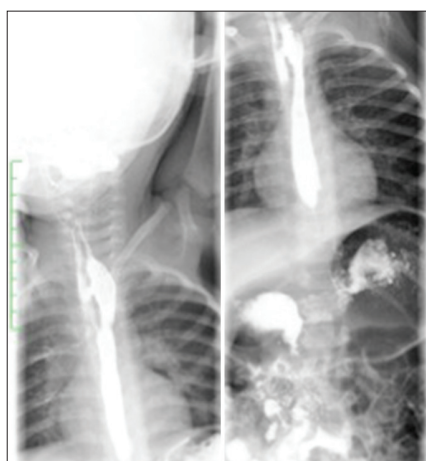


Figure 1: Barium swallow

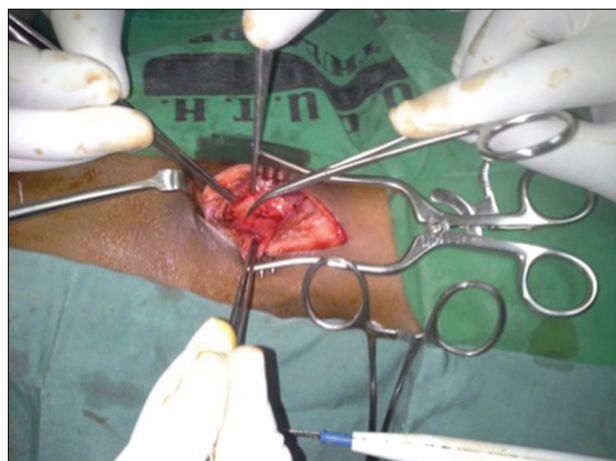

Figure 2: Exposed tracheo-esophageal fistula

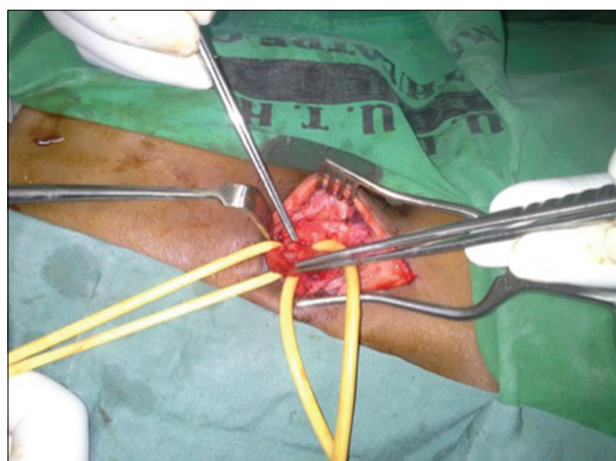


Figure 3: Divided fistulous tract

## DISCUSSION

Disc battery is a small single-cell battery shaped as a squat cylinder typically 5–25 mm in diameter and 1–6 mm high – like a button on a garment, hence the name. Button cells are used to power small

portable electronic devices such as wrist watches, pocket calculators, artificial cardiac pacemakers, implantable cardiac defibrillators, and hearing aids. Thinner variants are usually called coin cells.

The disc or button batteries are small, disc-shaped power units commonly used in digital watches, hearing aids, calculators, cameras, blood glucose meters, some toys, and other electronic instruments. They contain corrosive and toxic chemicals that can lyse or digest soft tissues leading to perforation. These include mercury, zinc, silver, nickel, cadmium, manganese, and lithium.<sup>[1,3-5]</sup>

Disc battery ingestion is seen in toddlers. There is no sex predilection, but in older age group, boys are said to be more commonly affected.<sup>[6,7]</sup>

Thoracic inlet has been reported to be the narrowest point and the most common site of foreign body impaction.<sup>[8]</sup> Our patient had the disc impacted at the thoracic inlet. The size of the battery plays a great role in impaction. Batteries that are > 20 mm are associated with a high risk of impaction.<sup>[8]</sup> The mean duration of impaction was reported to be about 5 h,<sup>[1]</sup> but our patient had the battery impacted for about 30 h. This time is enough for fistulation between the trachea and esophagus to occur.

The chemicals in these batteries can leak and lead to inflammatory reaction that will set the stage for perforation and fistula formation. There are different mechanisms by which these batteries cause damage. It can be caused by any of the following: Alkaline electrolyte leakage from the battery, “de novo” alkali production from external current, heavy metal toxicity, direct flow of current causing low-voltage burn, and pressure necrosis. Perforation occurs within hours of exposure to the battery substances.<sup>[9,10]</sup> Our patient had the battery impacted for about 30 h before it was removed. There was enough contact time between the disc battery and mucosa which led to the development of the fistula.

Most button battery ingestions go unnoticed as such the diagnosis can be missed. They may present in emergency department with dysphagia, refusal to eat, drooling of saliva, choking, coughing, stridor, vomiting, gagging, regurgitation, and cyanosis. Distal esophageal foreign body produces nonspecific symptoms such as fever, irritability, lethargy, poor appetite, and dehydration. Many children with esophageal foreign body may be asymptomatic.<sup>[11-13]</sup> Our patient presented with the features of recurrent respiratory tract infection despite various forms of treatments.

Neck X-ray (antero-posterior and lateral view) – this is readily available, cheap, and has a high accuracy in diagnosing radiopaque objects. This will aid in identifying the location of the battery.<sup>[14,15]</sup> In patients who have already developed the fistula after removal, chest X-ray may only show the features of respiratory tract infection, which can be misleading to the managing physician.

Chest X-ray can localize radiopaque objects lodged in the intrathoracic esophagus. If a fistula has developed, chest X-ray will demonstrate the effects of repeated respiratory tract infection.

Abdominal X-ray may localize intra-abdominal segment of the esophagus. This segment is short about 3–4 cm. This film can

also localize any foreign body that has passed to the stomach and bowel.

Barium swallow will demonstrate the site, width, length, and direction of the fistula.<sup>[16,17]</sup> It may also demonstrate contrast in the tracheobronchial tree and lung fields.

Endoscopy is the best diagnostic modality as it enables visualization of the fistula if it is wide enough. Mucosal folds may cause small fistulae to be missed.

Flexible and rigid bronchoscopy is employed to identify the fistula. Broncho-alveolar lavage can be instituted at the same time to clear the respiratory tract.<sup>[16,18,19]</sup>

Toxicology studies is required for the determination of blood and urine levels of toxic substances.<sup>[20-23]</sup>

### Treatment

Patients who perforate at the time of retrieval should be made to observe the following:

1. Nil by mouth and intravenous fluid
2. Broad spectrum antibiotics
3. Appropriate analgesics
4. Use of steroids is controversial
5. Contrast esophagogram before the child is allowed to eat. This should be repeated in 3–6 weeks to evaluate the presence of a stricture.

Nonoperative treatment tracheo-esophageal fistula – spontaneous closure has been reported in some of these patients.<sup>[24]</sup>

Endoscopic cauterization with sodium hydroxide, endoscopic excision, and closure with fibrin glue have all been reported.<sup>[25]</sup> Esophageal stenting has also been reported, especially in patients who are not fit for the surgery.<sup>[26,27]</sup>

Surgical treatment – the principles of repair of tracheo-esophageal fistula are:

1. Treat pre-existing pulmonary infections
2. Separate closure of the fistulous tracts on the tracheal and esophageal ends
3. Interposition of viable muscle flap between the tracheal and esophageal suture lines.

General anesthesia is the preferred anesthesia of choice in these patients. A cuffed endotracheal tube is far beyond the fistula. This has been reported to prevent anesthetic gas loss in the stomach.<sup>[28]</sup> A nasogastric tube should be inserted and regularly aspirated to prevent gastric distension with anesthetic gases. This tube will also serve as a mark to identify the esophagus intraoperatively.<sup>[29]</sup>

Proximal tracheo-esophageal access is via a low cervical incision, the fistula is divided and closed in two layers after which, it is buttressed with skeletal muscle flap from the neck or intercostal muscles.<sup>[30]</sup>

Intrathoracic tracheo-esophageal fistula access here is via a right posterolateral thoracotomy with the head end of the bed elevated

to prevent the reflux of gastric content into the trachea. The fistula is isolated, divided, and repaired. The repair is reinforced with mediastinal pleura.<sup>[31]</sup>

The goal is early extubation so as to avoid prolonged ventilation as this may compromise the suture line. Various postoperative analgesics have been used.<sup>[32]</sup>

### CONCLUSION

Disc battery ingestion can cause acquired tracheo-esophageal injury. It results from damage caused by the leakage of chemical constituent of the disc. If patients present within 2 h of ingestion, the chances of perforation are less and these group of patients can be managed nonoperatively. Once they present with a fistula, surgical repair offers the best outcome.

### Financial support and sponsorship

Nil.

### Conflicts of interest

There are no conflicts of interest.

### REFERENCES

1. Thabet MH, Basha WM, Askar S. Button battery foreign bodies in children: Hazards, management, and recommendations. *Biomed Res Int* 2013;2013:846091.
2. Abdulkareem I, Sabir OM, Elamin A. Button battery induced traumatic tracheoesophageal fistula: Case report and review of literature. *Sudan J Paediatr* 2011;11:43-9.
3. Khaleghnejad Tabari A, Mirshemirani A, Rouzrokh M, Seyyedi J, Khaleghnejad Tabari N, Razavi S, et al. Tracheoesophageal fistula following disc battery ingestion and foreign body impaction. *Caspian J Intern Med* 2011;2:336-9.
4. Chang YJ, Chao HC, Kong MS, Lai MW. Clinical analysis of disc battery ingestion in children. *Chang Gung Med J* 2004;27:673-7.
5. Banerjee R, Rao GV, Sriram PV, Reddy KS, Nageshwar Reddy D. Button battery ingestion. *Indian J Pediatr* 2005;72:173-4.
6. David TJ, Ferguson AP. Management of children who have swallowed button batteries. *Arch Dis Child* 1986;61:321-2.
7. Litovitz T, Whitaker N, Clark L, White NC, Marsolek M. Emerging battery-ingestion hazard: Clinical implications. *Pediatrics* 2010;125:1168-77.
8. Slamon NB, Hertzog JH, Penfil SH, Raphaely RC, Pizarro C, Derby CD. An unusual case of button battery-induced traumatic tracheoesophageal fistula. *Pediatr Emerg Care* 2008;24:313-6.
9. Langkau JE, Noesges RA. Esophageal burns from battery ingestion. *Am J Emerg Med* 1985;3:265.
10. Kuhns DW, Dire DJ. Button battery ingestions. *Ann Emerg Med* 1989;18:293-300.
11. Yardeni D, Yardeni H, Coran AG, Golladay ES. Severe esophageal damage due to button battery ingestion: Can it be prevented? *Pediatr Surg Int* 2004;20:496-501.
12. Cheng W, Tam PK. Foreign-body ingestion in children: Experience with 1,265 cases. *J Pediatr Surg* 1999;34:1472-6.
13. Sigalet D, Lees G. Tracheoesophageal injury secondary to disc battery ingestion. *J Pediatr Surg* 1988;23:996-8.
14. Crysdale WS, Sendi KS, Yoo J. Esophageal foreign bodies in children 15-year review of 484 cases. *Ann Otol Rhinol Laryngol* 1991;100(4 Pt 1):320-4.
15. Utley JE, Dillon ML, Todd EP, Griffen WO, Zeok JV. Giant tracheoesophageal fistula: Management by esophageal diversion. *J Thorac Cardiovasc Surg* 1978;75:373-7.
16. Diddee R, Shaw IH. Acquired trachea-oesophageal fistula in adults.

- Continuing education in anaesthesia. *Crit Care Pain* 2006;6:105-8.
17. Couraud L, Ballester MJ, Delaisement C. Acquired tracheoesophageal fistula and its management. *Semin Thorac Cardiovasc Surg* 1996;8:392-9.
  18. Seyedhejazi M, Sheikhzadeh D, Aliakbari Sharabiani B. Tracheo-esophageal fistula after disc battery ingestion. *J Cardiovasc Thorac Res* 2009;1:47-9.
  19. Bhat VS, Al-Saadi KA, Bessiouni IE, Tuffaha AS. Embedded esophageal foreign body. A diagnostic challenge. *Saudi Med J* 2009;30:433-5.
  20. Litovitz T, Schmitz BF. Ingestion of cylindrical and button batteries: An analysis of 2382 cases. *Pediatrics* 1992;89(4 Pt 2):747-57.
  21. Chan YL, Chang SS, Kao KL, Liao HC, Liaw SJ, Chiu TF, et al. Button battery ingestion: An analysis of 25 cases. *Chang Gung Med J* 2002;25:169-74.
  22. Kulig K, Rumack CM, Rumack BH, Duffy JP. Disk battery ingestion. Elevated urine mercury levels and enema removal of battery fragments. *JAMA* 1983;249:2502-4.
  23. Mant TG, Lewis JL, Mattoo TK, Rigden SP, Volans GN, House IM, et al. Mercury poisoning after disc-battery ingestion. *Hum Toxicol* 1987;6:179-81.
  24. Studley JG, Linehan IP, Ogilvie AL, Dowling BL. Swallowed button batteries: Is there a consensus on management? *Gut* 1990;31:867-70.
  25. Grisel JJ, Richter GT, Casper KA, Thompson DM. Acquired tracheoesophageal fistula following disc-battery ingestion: Can we watch and wait? *Int J Pediatr Otorhinolaryngol* 2008;72:699-706.
  26. Yata S, Kaminou T, Hashimoto M, Ohuchi Y, Sugiura K, Adachi A, et al. Successful closure of intractable tracheoesophageal fistula using a combination of a modified silicon stent and metallic stents. *Acta Radiol Short Rep* 2012;1. pii: arsr. 2012.110005.
  27. Liu YH, Ko PJ, Wu YC, Liu HP, Tsai YH. Silicone airway stent for treating benign tracheoesophageal fistula. *Asian Cardiovasc Thorac Ann* 2005;13:178-80.
  28. Paraschiv M. Tracheoesophageal fistula – A complication of prolonged tracheal intubation. *J Med Life* 2014;7:516-21.
  29. Robins B, Das AK. Anesthetic management of acquired tracheoesophageal fistula: A brief report. *Anesth Analg* 2001;93:903-5.
  30. Samad L, Ali M, Ramzi H. Button battery ingestion: Hazards of esophageal impaction. *J Pediatr Surg* 1999;34:1527-31.
  31. Freire JP, Feijó SM, Miranda L, Santos F, Castelo HB. Tracheo-esophageal fistula: Combined surgical and endoscopic approach. *Dis Esophagus* 2006;19:36-9.
  32. Darbari A, Suryavanshi A, Tandon S, Chandra G, Singh PK. Non-malignant tracheoesophageal fistula: Our experience. *Indian J Thorac Cardiovasc Surg* 2005;21:272-6.